

Systematic review: Acute abdomen in paediatrics

José Daniel Alvarado Ríos¹, Mariana Guadalupe Pineda González², Mario Alvarez Nava²,
Miriam Deyanira Rodríguez Piña², Brian Emmanuel Díaz Gordillo², Hugo Mendieta Zerón^{1,2,3}

Abstract

Introduction. Abdominal pain is a frequent reason for consultation in the emergency department, being the result of various pathologies, mostly of benign origin. However, the lack of timely identification and treatment can lead to significant complications. **Objective.** The purpose of this review is to deepen in the etiology of acute abdomen in pediatric patients. Accurate identification of the underlying cause not only enhances early diagnosis, but also plays a crucial role in mitigating potential complications. A thorough understanding of the origin of this condition lays the foundation for the implementation of more accurate treatments, with a positive impact on medical care. **Methodology.** An exhaustive literature search was conducted in renowned databases such as Pubmed, Google Scholar, ScienceDirect and Springerlink, as well as in medical literature, during the period from June to December 2021. This systematic review addresses the essentials of the topic of Pediatric Acute Abdomen, a frequent clinical entity in both emergency settings and pediatric primary care. Of note is the lack of familiarity with this phenomenon, as well as the need for studies addressing the predominant causes according to different pediatric age groups. In addition, there is a notorious lack of specific data on this phenomenon in the context of pediatric health in Mexico. **Conclusions.** This analysis aims to fill this gap, providing a more complete and detailed view on acute abdomen in pediatric patients, underlining the urgency of further research to enrich our understanding of this pathology in the Mexican setting.

Keywords: abdominal pain, acute abdomen, pediatric patient, diagnosis, evaluation, medical education.

1.Ciprés Grupo Médico.

2.Universidad Autónoma del Estado de México.

3.Hospital Materno Perinatal "Mónica Pretelini Sáenz".

Corresponding author:
Hugo Mendieta Zerón
E-mail: hmendietaz@gmail.com
ORCID: <https://orcid.org/0000-0003-3492-8950>

► <https://doi.org/10.22490/24629448.7534>

Introduction

The International Association for the Study of Pain (IASP) defines pain as “*an unpleasant sensation and emotional experience in response to actual or potential tissue damage*”. Acute pain is primarily due to sudden tissue, parenchymal or organ injury due to a postoperative event, trauma or, among others. (1) “Acute abdomen” (AA) is characterised by a 48-72 hours progression, with pain which is continuous, severe, localised or generalised and painful at abdominal palpation, in addition to deterioration of general condition. “Acute abdomen” (AA) is characterised by a 48-72 hours progression, which is continuous and severe. In addition to deterioration of general condition and painful abdominal palpation. (2) Also, it constitutes a set of signs and symptoms; like nausea, vomiting and fever, that manifest the existence of an intra-abdominal disorder that may require surgical intervention. (3)

Within the emergency department and primary paediatric care, abdominal pain is usually one of the most frequent reasons for consultation and in most cases tends to originate from non-surgical causes, which is why an adequate differential diagnosis is necessary according to its presentation in acute episodes, and intermittent and recurrent abdominal pain. Diagnosis and therapeutic follow-up depend on the patient’s age, as the causes are different with development.

Acute abdomen is a spectrum of diseases that have insidious and unbearable pain as a common feature; depending on its location in different quadrants of the abdomen, it can indicate the root of the etiology. (2) This spectrum requires an in-depth study of the causes, because despite being a common entity in the paediatric population, the symptomatology is ambiguous, not to mention that in this age group, infants manifest pain through crying, making early diagnosis difficult; this is often unnecessary because it is based on an erroneous examination (4) or because the peritoneal innervation is too extensive, which causes more intense pain than the real source. (5)

Acute appendicitis is generally one of the most common causes of surgical acute abdomen in children, although it can be difficult to differentiate from other aetiologies. (6) Based on acute abdomen, Villegas (October 2017) mentions: “*the most frequent surgical conditions in pediatric patients are appendicitis, and intussusception (the most common cause of intestinal obstruction, between three months and six years of age, 90% of cases occur before 24 months of age)*”.

Despite efforts to make imaging a more accurate diagnosis, clinical manifestations, as well as physical examination, remain the cornerstone of diagnosis. (7) The aim of this review is to analyse and unify the existing information on acute abdomen in the paediatric population.

Etiology

There are multiple classifications to find the aetiology of acute abdomen in paediatric patients, for example, the location of the pain. Figure 1 shows a scheme that

illustrates the most common aetiology of AA, in relation to the region where the pain is located:

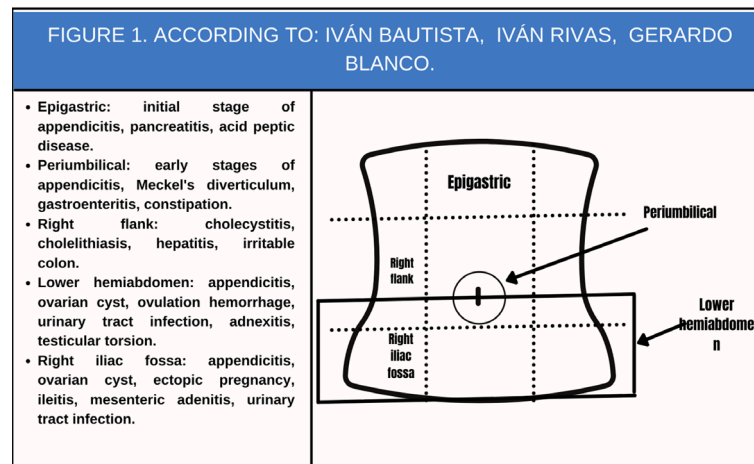


Figure 1. Own elaboration based on 8. Antonio J, Cadenas A, De La M, Espí T. Diagnóstico y tratamiento del dolor abdominal agudo (abdomen agudo) en Urgencias. Soc Española Urgencias Pediátricas [Internet]. 2020;1:197–213. Available from: www.aeped.es/protocolos/

The aetiology of acute abdomen varies according to the age of the patient, as observed in the study carried out by the Paediatric Emergency Department, Hospital Infantil Universitario Niño Jesús, Madrid, Spain, the aetiologies of AA most frequently found in patients under two years of age are: intestinal invagination, acute appendicitis, intestinal volvulus, incarcerated hernia; in children from 2 to 5 years of age: acute appendicitis, incarcerated hernia, Meckel's diverticulum, intestinal obstruction due to previous surgery, tumours; in children over 5 years of age: acute appendicitis, Meckel's diverticulum, intestinal obstruction due to previous surgery, tumours: acute appendici-

tis, incarcerated hernia, Meckel's diverticulum, intestinal obstruction due to previous surgery, tumours; in children older than 5 years: acute appendicitis, inflammatory bowel disease (IBD), cholecystitis, pancreatitis, diabetic ketoacidosis, testicular/ovarian torsion, nephritic colic and tumours; while in adolescents the following stand out: acute appendicitis, testicular/ovarian torsion, pelvic inflammatory disease, nephritic colic, cholecystitis, pancreatitis, hepatitis, IBD, tumours and ectopic pregnancy in the case of the female sex. (8)

Finally, and with a focus on the current perspective of the COVID-19 pandemic, a

study was conducted in the Department of Paediatric Surgery, Hospital Universitario Pediátrico Niño Jesús in Madrid, Spain in patients under 18 years of age with a clinical diagnosis of suspected acute abdomen with COVID-19. In all cases the reason for ED consultation was abdominal pain, mainly generalised or localised in the left iliac fossa, associated with fever, vomiting and diarrhoea. This retrospective observational study concluded that SARS-CoV-2 infection can cause digestive symptoms as the first clinical manifestation, simulating AA. It is therefore important to perform a good differential diagnosis, a good clinical history and a complete physical examination, not forgetting blood tests and imaging, to avoid paediatric inflammatory multisystemic syndrome. (9) With this evidence it can be said that a possible new cause of acute abdomen in the paediatric age group is derived from SARS-CoV-2 disease.

Pathophysiology

The pathophysiology of the acute abdomen (AA) is addressed by studying its main and most frequent expression: abdominal pain. The definition of pain according to the International Association for the Study of Pain (IASP) states that: *“Pain is an unpleasant sensory and emotional experience associated with or similar to actual or potential tissue damage”*, being abdominal pain as long as it is located in this specific anatomical

region even if the damage is not located in any abdominal structure. (10)

To approach the type of acute abdominal pain, it was classified according to its origin and its pathophysiological mechanism. Depending on its origin, it is subdivided into abdominal and extra-abdominal pain, the former considers the damage in any segment of the digestive tract, either solid viscera or abdominal structure (spleen, pancreas, liver, gallbladder or mesentery), as well as damage to the genitourinary system, spine, skin or soft structures of the abdominal wall (2), while the extra-abdominal pain is that damage whose origin is in structures far from the abdomen, such as the thorax.

To understand the pathophysiological mechanisms of abdominal pain, we must be clear about some basic points about the receptors, the stimuli and their distribution in the organs involved, as well as their classification into three categories: visceral, parietal and referred.

Pain receptors (nociceptors) are free nerve endings located in various tissues that are sensitive to mechanical, thermal and chemical stimuli (11) with little or sometimes no adaptation to them; Regarding AA, their location in the wall of the hollow viscera, in the capsules of solid organs, in the parietal peritoneum (the visceral peritoneum lacks these receptors) and in the mesentery must be remembered, as well as the predominant painful stimuli in these structures, which

are mechanical and chemical, represented by distension, ischaemia and inflammation respectively, the latter mainly in the mucosa of the hollow viscera, which are especially sensitive to chemical stimuli. (12)

The receptors when excited will generate an electrical signal which travels along specific nerves depending on the damaged tissue and the type of painful stimulus involved, factors which together with the patient's own characteristics, such as pain threshold, will define the different characteristics of pain.

Symptomatology

An in-depth study of the patient's symptoms will allow the clinician to make a diagnosis and adopt an appropriate course of action to speed up patient care and avoid excessive requests for laboratory and imaging studies that would delay the resolution of the condition.

We divide the important symptoms to investigate in the course of the AA that accompany the pain into two categories: digestive and extra-digestive symptoms. (2) Digestive symptoms include: vomiting, diarrhoea and constipation, while extradiigestive symptoms include: fever, voiding symptoms, cough, rectal bleeding and gynaecological symptoms in adolescents. (15)

Digestive symptoms include:

- Vomiting: It is very unspecific and can accompany almost any childhood

pathology. Despite this, some of their characteristics point to the existence of an important organic pathology (surgical or otherwise). (15) Food vomiting, bilious vomiting, faecal vomiting that are persistent and follow pain are indicative of surgical pathology. (2)

- Alterations in bowel habits: It is important to know whether diarrhoea or constipation and the presence of mucus, pus or blood in the stool coexist with the pain, as this will indicate the cause. For example, the most frequent cause of pain with vomiting and diarrhoea is acute gastroenteritis, although it may also be the clinical presentation of appendicitis (stools of a soft and scanty consistency may appear), mainly retrocecal. (15,16) Inflammatory bowel disease (IBD) or haemolytic-uraemic syndrome (HUS) must always be considered. In the case of isolated constipation, it is a frequent finding in non-specific abdominal pain, but when it is associated with vomiting: a bowel obstruction syndrome must be ruled out. (12)
- Hematochezia: The presence of blood in faeces with a redcurrant jam - like appearance in an infant accompanied by colicky abdominal pain makes it necessary to look for intussusception, however, it is a late sign appearing in only 15-20% of cases. The most common cause in older children is IBD. (15)

Extradigestive symptoms are:

- **Fever:** if it appears concomitantly with alteration of the general condition, it is suggestive of surgical pathology. (2) In acute appendicitis it is moderate (38-38.5 °C) hours after the onset of pain, while in gastroenteritis, it appears from the beginning and may be high (39 °C) in enteroinvasive or low (37.5-38 °C) in viral aetiology. When fever is higher than 40°C from the onset, it suggests infectious pathology. (15)
- **Urinary symptoms:** Dysuria with pollakiuria and urgency should raise suspicion of urinary tract infection. It is important to investigate for polyuria and polydipsia because patients with diabetic ketoacidosis may report significant abdominal pain simulating surgical AA. (2,15)
- **Respiratory symptoms:** The presence of respiratory symptoms will force us to rule out lower lobe pneumonia, derived from the fact that children with respiratory distress or pneumonia may complain of abdominal pain. (2) The presence of cough, dyspnoea and fever should be questioned.
- **Gynaecological symptoms (in adolescents):** In adolescents who have already had menarche, the date of the last menstrual period should always be asked, and the possibility of ectopic

pregnancy, miscarriage or dysmenorrhoea should be considered in case of acute abdominal symptoms. When the patient has a Tanner scale of less than IV and no menarche, imperforate hymen should be considered. (15)

Diagnosis

The diagnosis of AA is always a challenge for the clinician and is more complex in the paediatric age group, especially in the non-verbal child (neonate, intubated infant, infant with disabilities or of foreign origin) because he/she is deprived of the essential means to communicate his/her experience with the limitations that this entails. (1)

The clinical history and physical examination become an opportunity to build a solid relationship with the child's parents. (17)

This process is based on a thorough collection of anamnestic data, a methodical physical examination and a rational request for complementary tests, remembering that an adequate history and a thorough physical examination are the cornerstone for establishing the diagnosis. (1) Before starting the diagnostic process, it is essential to know the main pathologies that cause acute abdominal pain according to age groups and their frequency. (2)

Anamnesis

The history taking should allow both the parents and the child to describe the entire chronology of evolution. (17) It is important to carry out an anamnesis aimed at seeking oriented data that should include the following information:

Pathological history: it is important to know the presence of a history of abdominal surgery or similar previous episodes, medications received, accidental or intentional ingestion of drugs, as well as a history of trauma or underlying diseases. (2) In the specific case of adolescent women, it is of utmost importance to collect gynaecological history, including the date of the last menstrual period, as well as the presence of risky sexual behaviour with the use or not of contraceptive methods. (16)

When taking the history we must approach the semiology of pain carefully, as it poses a significant diagnostic challenge due to the wide variety of underlying causes and also the inability of the child or parents to describe it. (5)

Location: We can classify it according to where the pain is located; epigastric (pain originating in the liver, pancreas, biliary tract, stomach and upper intestine), periumbilical (originating in the distal part of the intestine or in the cecum and proximal colon), hypogastric or suprapubic (originating in the distal part of the large intestine,

urinary tract or pelvic organs), generalised (found in cases of referred pain originating in other non-abdominal organs) and sacral (related to pain originating in the rectum). In general, the more distal to the umbilicus the location of the pain, the greater the risk of surgical pathology. (16)

Intensity: This is a key point, not only for diagnosis, but also for the correct treatment of pain and its subsequent reassessment. Commonly the subjective assessment of pain by the physician does not correlate reliably with the pain actually felt by the patient; this is an important limitation in newborns and infants, which reduces its difficulty in preschool children. Because of the above problem, objective tools have been proposed and established to assess pain in the paediatric age group. It is recommended to use validated scales, depending on the age of the child, to establish pain intensity. (16)

The purpose of using age-appropriate scales is to objectify the subjective. Both the reliability and validity of these tools have been regularly verified, allowing us to rely on these data in a scientific manner and thus to adapt our pharmacological treatment. (1) Although we can rely on the scales, we must always compare them with the patient's clinical history, evolution and associated treatments, and keep in mind the possibility of the child lying (preschool age and beyond). Table 1 summarises the tools used by age in the child.

Table 1. Own elaboration based on Annequin D, Ngo J. Assessment and management of pain in neonates, children and adolescents. EMC - Tratado Med [Internet]. 2019;23(1):1-6. Available from: [https://doi.org/10.1016/S1636-5410\(18\)41701-1](https://doi.org/10.1016/S1636-5410(18)41701-1).

PAIN ASSESSMENT TOOLS BY AGE	
0 to 4 years old	Behavioral heteroevaluation by observation of the child. Neonatal pain and discomfort scale (EDIN) Neonatal Infant Pain Scale (NIPS) Pediatric Pain Evaluation Scale (EVENDOL) for estimating pain in children under 7 years of age in the emergency department. Verbal Rating Scale (VRS)
4 to 6 years old	Faces Pain Scale-Revised
From 6 years of age	Visual analog scale (VAS) with a vertical slider Numeric Pain Rating Scale: «rating between 0 and 10»

Mode of presentation: It is classified as acute (usually indicating mechanical processes such as intestinal perforation, ectopic pregnancy, intussusception, testicular torsion or ovarian torsion); gradual (in inflammatory processes, such as appendicitis, pancreatitis or cholecystitis); or intermittent (in gastroenteritis or colic, usually corresponding to referred pain in the biliary tract or its ducts): appendicitis, pancreatitis or cholecystitis); or intermittent (in gastroenteritis or with colicky character it usually corresponds with referred pain of the bile ducts or their ducts, pancreatic ducts or urinary tract, uterus or fallopian tubes). (2,16)

Duration: Intense pain lasting more than six hours points to a surgical pathology. It is important to know the relieving and aggravating factors of pain, for example, abdominal pain in appendicitis tends to worsen with movement and subside with rest, while pain that worsens with urination should suggest a urinary origin. (16)

Type of pain: it is classified as colicky, stabbing (suggesting obstruction of the gastrointestinal or genitourinary tract) or continuous (related to acute inflammatory processes). (16) Diffuse pain usually occurs in evolved situations of the above processes. On the other hand, it is essential to know if there is irradiation of the pain.

Physical examination

Initial assessment

When the patient arrives at the ED, an initial assessment and stabilisation should be performed using the Paediatric Assessment Triangle and the ABCDE sequence (15), which can be applied to identify major physiological problems and initiate initial stabilisation, based on assessment of appearance, work of breathing and colouring. (16)

If there is Central Nervous System dysfunction (due to pain or poor cerebral per-

fusion) or in case of shock (compensated or decompensated), the patient should be stabilised before taking a detailed history and physical examination. Vital signs are measured and a peripheral venous line is cannulated for capillary glycaemia, intravenous fluids are administered and supplemental oxygen is provided if necessary. (15)

Assessment of pain intensity: It is a priority to assess pain using an age-appropriate scale to allow reliable determination of pain intensity in order to administer the most appropriate analgesic treatment. (15,16)

General physical examination

It is of utmost importance, whenever possible, to empathise with the child and gain their trust in order to facilitate an adequate examination. It should be thorough and complete with inspection of the abdomen in its entirety, including the otorhinolaryngological area (acute pharyngotonsillitis or otitis), chest, genitalia and skin inspection (15), which should always be performed since abdominal pain is commonly a non-specific symptom related to extradiagnostic pathology. (16)

It is important to assess the severity of the patient's condition through consciousness and activity. Vital signs should be taken on a case-by-case basis, with temperature (to assess the presence of fever) and weight in all patients, as well as hydration status. (15)

We must assess for signs of haemodynamic instability (the presence of tachycardia may suggest compensated shock due to sepsis or hypovolaemia, while hypertension is present in Schönlein-Henoch purpura or as a result of haemolytic-uraemic syndrome, and hypovolemic shock in an adolescent may be related to ectopic pregnancy). If dyspnoea is present, we should assess for oxygen saturation and respiratory rate (the presence of rapid breathing with abdominal pain suggests peritonitis or pneumonia; Kussmaul-type breathing may be related to diabetic ketoacidosis). (15)

Always look for signs of possible extra-abdominal causes such as pneumonia, urinary tract infections and meningitis. In the skin the presence of purpura suggests Schönlein-Henoch purpura, if erythema nodosum and granulosa pyoderma are present it suggests inflammatory bowel disease.

Abdominal examination

Physical examination of the abdomen

Inspection: This begins with observation of the child's behaviour and attitude on the examination table in search of scars from previous surgery, external signs of bowel movements, bultomas (incarcerated hernias), distension, haematomas (trauma and in unusual locations due to leukaemia, haemophilia or maltreatment), petechiae, purpura, jaundice (in haemolytic crisis, in

acute gallbladder pathology or hepatitis), external inflammation, tumours or masses (inguinal or scrotal) and skin lesions which may be exanthematous (rash) due to viral infections or anaphylaxis, or on the other hand, localised such as erythema nodosum or pyoderma gangrenosum. (15,16)

Auscultation: This is performed in all quadrants of the abdomen to assess whether peristalsis is increased, decreased or alternating. (16) If there is an increase in the hydro-aerial sounds, gastroenteritis is suspected; the presence of abdominal sounds with signs of struggle alternating with periods of silence suggest obstruction. A decrease in abdominal sounds suggests peritonitis, and a complete absence of abdominal sounds suggests ileus. (15) The cardiopulmonary system should be auscultated if it is suggestive of pulmonary pathology.

Percussion: We can assess the presence of tympanism. The presence of generalised tympanism will suggest meteorism or, on the contrary, if there are warning signs, it is associated with obstructive or peritonitis syndromes (intestinal obstruction or perforation). (15,16)

Palpation: Should be performed in a gentle and relaxed manner, assessing the patient's expression in order to obtain their cooperation while looking for rigidity and masses. (15) Starting with the quadrant furthest away from the pain in a gentle manner, and finally, we locate the area of greatest painful

intensity, observing the child's expression to locate the area of maximum pain. (15,16)

Finally, we perform the different appendicular signs: Psoas, Rovsing, Blumberg or gallbladder pathology (Murphy). Signs of peritoneal irritation strongly suggest surgical pathology. (15,16)

Deeper palpation may reveal abnormal abdominal masses (intussusception, abscesses, tumours) and visceromegaly (splenic sequestration or haemolytic crisis in patients with sickle cell disease) which should be evaluated. (15,16)

Anatomical correlation of the nine quadrants into which the abdomen is divided is the mainstay of the physical examination, and a systematic approach pattern is required together with established anatomical knowledge so that vital details are not overlooked.

External genitalia: Inspection and palpation of the external genitalia is indispensable for the correct assessment of abdominal pain. In the male, the existence of balanitis or urethritis justifies the existence of acute abdominal pain. (16)

Testicular inflammation with hydrocele leads us to suspect possible involvement of the spermatic cord, testicular torsion or inguinal hernia. Gynecological examination should be performed in girls who report vaginal discharge, sexually active adolescents, as well as in all cases of suspected

sexual abuse. (15,16) The most common causes of abdominal pain of gynaecological origin in paediatrics are evolving clinical expressions of an imperforate hymen or vaginal atresia.

Rectal examination: This is an examination that is uncomfortable for the patient, and is not currently recommended unless necessary, as well as in suspected peritoneal syndrome, to determine whether there is lateralized pain at the level of the cul-de-sac of Douglas or a mass effect, to assess whether there is anal stenosis, sphincter tone, palpable masses and, finally, the size and presence of faeces in the rectal ampulla (useful in the assessment of faecal impaction). (16) It will be full of faeces in functional constipation and empty in Hirschsprung's disease. (15) It also helps to assess internal genitalia in girls, as it facilitates palpation of the cervix and corpus uteri, as well as adnexal swelling.

Active manoeuvres: Evaluate the following manoeuvres: sitting up from a lying position, lifting the legs or attempting to jump, as they are limited in the case of peritoneal involvement. If the clinical history and examination do not provide a clear diagnosis, the patient should be placed under observation and the manoeuvres repeated. (15)

Complementary explorations

The extensive aetiology of AA confronts us with multiple possible complementary tests

and our conduct will be dictated by the clinical context of each patient so that we use them rationally.

They will be requested depending on the findings during the anamnesis and physical examination, as they allow us to orientate the cause of abdominal pain in most cases, so that a rational use of complementary explorations in the assessment of abdominal pain is recommended; it is relevant to mention that if there are no alarm signs or symptoms, no complementary test will be necessary. (15,16) If AA is suspected, radiological or laboratory tests should be performed to complete the evaluation.

Blood tests: In patients with incoercible vomiting or signs of dehydration on physical examination, the presence of water and electrolyte disorders, hypoglycaemia and impaired renal function should be ruled out (urea and creatinine levels will help in the assessment of renal function and hydration status). (16)

The presence of an elevated white blood cell count (with neutrophilia), as well as an elevation of acute phase reactants, suggests an infectious process as in the case of appendicitis, in some cases of cholecystitis and in about half of the cases of intestinal obstruction. (16) Anaemia points to pathology with blood loss. Examination of peripheral cells may reveal red blood cell destruction and thrombopenia, as in haemolytic-uraemic syndrome.

Liver and pancreatic enzyme studies are useful if the clinical history suggests liver or pancreatic pathology (serum levels of amylase, transaminases and lactate dehydrogenase will help in the diagnosis). (16)

Urinalysis: This should be performed whenever there is a voiding syndrome associated with abdominal pain and should be systematically indicated when abdominal pain affects infants, due to its relevance as a differential diagnosis. (16)

Pyuria and haematuria may be present in urinary tract infections and renal lithiasis, usually pelvic appendicitis may show isolated leukocyturia and/or microhaematuria associated with bladder irritation. If haematuria is associated with protheinuria, the possibility of Schönlein-Henoch purpura or haemolytic-uraemic syndrome should be evaluated. Ketonuria and glycosuria may be part of a diabetic debut. (16)

Pregnancy test: Should be considered in postmenarchal adolescent girls with acute abdominal pain. (16) A test to rule out the possibility of pregnancy should be performed prior to radiological studies. Secondly, it is used for the study of pregnancy situations, such as ectopic pregnancy.

Imaging in AA in paediatric patients: Due to the often nonspecific symptoms, imaging in the acute abdomen in childhood plays an extraordinarily important role, as it will guide the course of a surgical emergency towards surgical intervention or conservati-

ve treatment. The GOLD standard in these pathologies is abdominal ultrasound. (18)

Simple abdominal X-ray: Mainly in standing, supine or right lateral decubitus position. In most cases, it is not useful for diagnosis. (16) It is difficult to interpret and involves subjecting the patient to a non-negligible source of radiation.

Current recommendations are not to routinely perform abdominal radiographs in children with abdominal pain. The silhouette, size and location of the kidneys, liver and spleen should be assessed. The borders of the psoas should be sharp. Pathological findings include hydroaeric levels, dilated or thickened loops and the presence of pneumoperitoneum or intestinal pneumatosis (15).

Chest X-ray: Confirms the diagnosis of pneumonias that may simulate acute abdomen. It is recommended when alterations in respiratory auscultation are found, as well as in patients under 3 years of age with catarrhal symptoms and persistent fever associated with abdominal pain. It is diagnostic in intussusception (16) and can aid in the diagnosis of acute appendicitis. Occasionally, it can reveal the presence of mesenteric adenitis, help in the diagnosis of pancreatic and gallbladder pathology and hydronephrosis.

Abdominal ultrasound: Female genital ultrasound is very useful for the diagnosis of adnexal pathology (ovarian cysts, ovarian

torsion and presence of pregnancy); while testicular doppler ultrasound can be useful in certain cases of acute scrotum such as testicular torsion and epididymitis. (16)

Bedside abdominal ultrasound by trained clinicians is a tool increasingly used for the assessment of traumatic or non-traumatic abdominal pain, allowing early diagnosis, and thus speeding up treatment (16). It is widely useful in the assessment of acute abdominal pain and, compared to other scans, has the advantage of not subjecting the patient to radiation.

Abdominal computed tomography: This procedure has a high radiation exposure. Alternative imaging modalities will be our most common tools due to their greater diagnostic certainty without radiation exposure. If used, focused studies with low radiation dose are recommended.

Contrast CT is useful for the evaluation of patients with acute abdominal pain, when a wide variety of diagnoses are considered, it can help in tumours and abdominal trauma. In addition, it has a high sensitivity and specificity for diagnosing appendicitis and is the most sensitive imaging test for paediatric nephrolithiasis. (18)

Abdominal MRI: Not widely used for the assessment of acute abdominal pain in the child, because it is too time consuming and requires sedation, its usefulness in the diagnosis of acute appendicitis is similar to

that of computed tomography, without subjecting the patient to irradiation (16), a fact reaffirmed in an article where according to Warner *et al.* the appendix can be identified by MRI in most children, which is similar to the results of computed tomography reports. (19) It is used diagnostically to clarify unclear ultrasound findings. (18)

Treatment

In paediatric patients presenting with AA in the Emergency Room, ABCDE manoeuvres are performed to stabilise them, followed by analgesia, which is the cornerstone of treatment, and in the event of nausea and vomiting, antiemetics are administered. (8,20)

Once the patient is stabilised, the cause is sought through clinical examinations and imaging to confirm it, but in the meantime, priority should be given to identifying warning signs and symptoms that indicate a surgical emergency, placing them on serum therapy. (2)

The definitive treatment is chosen on the basis of the aetiology found, which is why it is divided into conservative or non-surgical and surgical; the former refers to treating the symptoms with analgesia and the infection found with broad-spectrum antibiotics for gram-negative bacteria. (8,20) The second consists of performing a laparoscopy or laparotomy, usually as an emergency procedure. Currently, laparotomy is more commonly

used because the literature reports that no complications were found after laparotomy, while in laparoscopy adhesions were seen some time after surgery. (21)

In the COVID-19 times it was reported that PCR should be performed in patients arriving with abdominal pain as this virus causes symptoms similar to AA but should not be operated on. (9)

Prognosis

The prognosis depends on the aetiology and early diagnosis, however, it has been reported that males are more likely to have a higher chance of surgery. (20,22) For symptoms resembling AA caused by COVID-19 the prognosis is good. (9)

Material and method

A search was made for articles in Pubmed, Google Scholar, ScienceDirect, Springerlink databases; and medical literature, said search was carried out from June to December 2021, about Acute Abdomen in paediatric patients.

Inclusion criteria:

1. Publication filter

- Articles pertaining to health sciences, focused on paediatric patients and no older than 5 years.

- An exception was made for a book published in 2008.
- Included were: review articles, case reports, descriptive studies, cohort studies, case-control studies, conferences and prospective studies.

2. Word filtering:

- Taking as keywords: paediatric acute abdomen, acute abdomen, children, paediatric, kids, kids, children, pain and the Boolean operators used: AND and OR. As an example: “paediatric acute abdomen OR acute abdomen in children”.

Exclusion criteria

- Texts whose focus was acute abdomen in adult patients were excluded.
- Texts that did not have paediatric acute abdomen as a central theme were discarded.
- Articles published before 2016.
- Articles on acute abdominal pain.

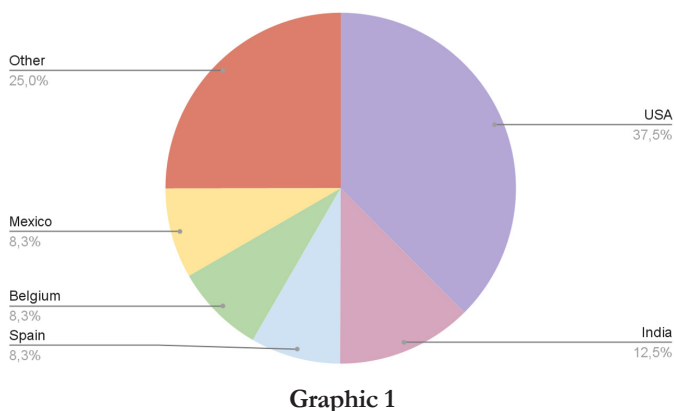
Results

Of the total number of articles found, those that met the exclusion and inclusion criteria were a total of 24, which were sorted into a database.

Based on this database, four columns were added to show the following characteristics:

- Country of origin.
- Types of study/documents.
- Most common causes.
- Year of publication.

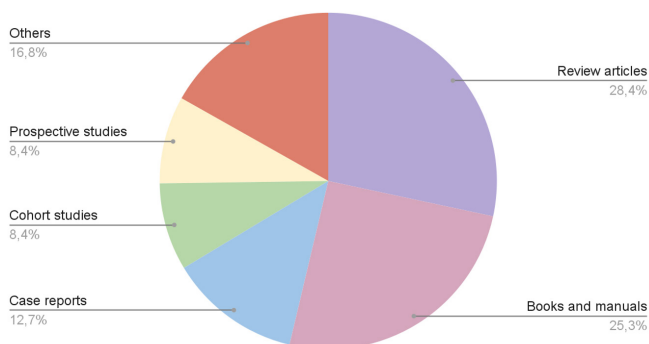
Of the 24 articles, 9 are from the United States of America, corresponding to 37.5%; 3 are from India, 12.5%; 2 are from Spain, 8.33%; 2 from Mexico, 8.33%; 2 from Belgium, 8.33%; leaving the remaining 6 from the following countries: Germany, Brazil, China, Ecuador, France and the Netherlands, which only included one article each, with a total percentage of 25%. The distribution is shown in graph 1.



Graphic 1

Review articles stood out in this systematic review with a total of 7.28%; within the literature (books, manuals), we found 6, 25%; 3 are case reports, 12.5%; 2 are cohort studies, 8.33%; 2 are prospective studies,

8.33%; and the remaining four are a narrative review, a case-control study, a descriptive observational study and a conference, 16.66%. (Graph 2)



Graphic 2

Of the information collected, 11 references (45.83%) did not provide conclusive information on the etiology of paediatric AA, while the remaining 13 references (54.16%) do mention etiology of paediatric AA. 16% do mention aetiologies, where the main surgical cause of paediatric AA is acute appendicitis, only 7 references explicitly state that it is the main surgical etiology in older children (not infants, not neonates, not under one year of age), the others, although not excluding appendicitis as the main surgical aetiology in older children, do not mention it either. Intussusception corresponds to one of the main surgical causes in children under two years of age (infants, neonates) according to 5 references and one reports it in children older than one year. Within the non-surgical pathologies of AA, out of 5 references, 4 mention that gastrointestinal

diseases (gastroenteritis, constipation), followed by infectious diseases of the respiratory tract, correspond to the main non-surgical pathologies.

PubMed was the database with the most references, with a total of 10, 41.66%; sciencedirect gave us 4, 16.66%; NCBI gave us 3, 12.5%; AEPED, journals and pole of knowledge gave us 3 more, 12.5%; and the remaining 3 belong to literature, 12.5% and one conference, 4.16%.

Discussion

A review of the literature was carried out, incorporating different studies on the acute abdomen in paediatric patients, to gather information to promote correct medical action based on basic knowledge of definitions and concepts, as well as epidemiology, etiology, pathophysiology, and predominantly the clinical expression of acute abdomen in this age group.

The cardinal symptom in these patients is reported to be a pain; however, the most common concomitant symptoms were also found to be fever, vomiting, abdominal hypersensitivity, diarrhea, painful urination, and even recurrent airway infections.

It was found that, regardless of the cause of acute abdomen in paediatric patients, especially in neonates and infants, communication is a barrier to diagnosis and

the physician must be prepared to perform an accurate history taking (usually with parents or primary caregivers), a complete physical examination supported by appropriate laboratory and laboratory tests, as well as the ability to offer treatment as quickly as possible. For the above reasons, it was gratifying to include pain assessment scales for paediatric pain useful in the ED as they are a great support for the physician faced with a neonatal or infant patient who does not yet have the linguistic ability to communicate.

This spectrum is variable and depends on each of the pathologies, however, it specifically encompasses only conditions affecting preschoolers, schoolchildren and adolescents (23). Newborns may present with necrotising enterocolitis. Midgut volvulus occurs 40% of the time in the first week of life, 50% in the first month and 75% in the first year. Intussusception usually occurs between 9 and 24 months of age. The most common cause of paediatric acute abdomen is appendicitis in children older than one year (20). Overall, acute appendicitis is the most common cause of surgical acute abdomen in all age groups and worldwide, although it can be difficult to differentiate from other causes of paediatric acute abdomen: morbidity in children is high, with an overall frequency of appendiceal perforation of 12.5% to 30%. Early and accurate diagnosis of acute appendicitis is important to avoid both a serious outcome and unnecessary surgery (6).

In a prospective observational study conducted between 2016-2017 by the department of Paediatric Surgery with the collaboration of Paediatric Emergency Department, Institute of Child Health, Sir Ganga Ram Hospital, New Delhi, where a total of 720 children were seen, and based on their final diagnosis they were divided into two groups: group I: 8% presenting with a surgical aetiology; leaving 92% of children with a non-surgical aetiology, it was concluded that: the cause of pain in more than 90% of children presenting to the paediatric emergency department with complaints of abdominal pain is non-surgical. Constipation was the most common diagnosis in these children, followed by acute gastroenteritis, other less common causes observed were: pain of uncertain aetiology and urinary tract infections and upper respiratory tract infections. In 8% of children whose aetiology of pain is surgical, acute appendicitis was found to be the most common surgical cause, although the aetiology will change according to the age of the patients. (5)

In newborns the most common causes reported were neonatal necrotising enterocolitis, intestinal atresia and intestinal malrotation: corresponding to surgical aetiologies; in the infant population, intussusception and incarcerated hernias were observed; in children older than 5 years and up to adolescence, appendicitis was reported as the most common cause; however,

some other causes observed were trauma and idiopathic peritonitis.

Extensive information was obtained on the clinical context in which the paediatric patient develops as the correlation between clinical, laboratory and laboratory findings in the paediatric patient is well known and guides through the many differential diagnoses.

Limitations of the study

Confusion between acute abdomen and acute abdominal pain, as well as its use of synonymy with acute abdomen. Although epidemiological information on the most frequent diagnoses of acute abdomen in paediatrics exists, it comes from other countries and there is a clear lack of reported data on the subject in Mexico.

Conclusions

This systematic review has been carried out with the aim of touching on the key points of the subject of Paediatric Acute Abdomen, as this is a fairly common pathology both in the emergency department and in paediatric primary care, and one with which we are not very familiar. There is a lack of further studies on the analysis of the most common causes according to paediatric age group, as well as more data on this phenomenon in Mexico.

References

- Annequin D, Ngo J. Evaluación y tratamiento del dolor en recién nacidos, niños y adolescentes. EMC - Tratado Med [Internet]. 2019;23(1):1–6. Available from: [https://doi.org/10.1016/S1636-5410\(18\)41701-1](https://doi.org/10.1016/S1636-5410(18)41701-1)
- Mendoza-rivilla DC, Barahona-moreta CI, Chang-alvarado PC, Independiente I, Independiente I, Independiente I, et al. Abdomen agudo pediátrico Pediatric acute abdomen Abdómen agudo pediátrico. 2021;6(5):1054–63.
- Rebeca D, Chico G, Francisco P, Mayoral V. Manual de Pediatría. 2016;229.
- Makin E, Davenport M. Evaluation of the acute abdomen. Paediatr Child Health (Oxford). 2016 Jun 1;26(6):231–8.
- Banerjee R, Prasad A, Gupta S. Clinical spectrum of acute abdomen in children admitted to pediatric emergency department: A prospective study. Curr Med Res Pract [Internet]. 2019;9(2):49–52. Available from: <https://doi.org/10.1016/j.cmrp.2019.02.002>
- Wang Z, Ye J, Wang Y, Liu Y. Diagnostic accuracy of pediatric atypical appendicitis: Three case reports. Medicine (Baltimore) [Internet]. 2019 [cited 2021 Aug 18];98(13). Available from: <https://pubmed.ncbi.nlm.nih.gov/32694387/>
- Villegas, Efrén. (octubre, 2017). *Abdomen agudo, Puntos clave en el diagnóstico*. Conferencia presentada en 4º Reunión Regional Y XV Encuentro de Profesionales en Salud Infantil. Hermosillo, Sonora.
- Antonio J, Cadenas A, De La M, Espí T. Diagnóstico y tratamiento del dolor abdominal agudo (abdomen agudo) en Urgencias. Soc Española Urgencias Pediátricas [Internet]. 2020;1:197–213. Available from: www.aeped.es/protocolos/
- Rico Espiñeira C, Souto Romero H, Espinosa Góngora R, Espinoza Vega ML, Alonso Calderón JL. Acute abdomen in COVID-19 disease: the pediatric surgeon's standpoint. Cir Pediatr [Internet]. 2021;34(1):3–8. Available from: <http://www.ncbi.nlm.nih.gov/pubmed/33507637>
- SN R, DB C, M C, NB F, H F, S G, et al. The revised International Association for the Study of Pain definition of pain: concepts, challenges, and compromises. Pain [Internet]. 2020 Sep 1 [cited 2021 Aug 18];161(9):1976–82. Available from: <https://pubmed.ncbi.nlm.nih.gov/32694387/>
- Hall JE, editor. Guyton Y Hall. Tratado de Fisiología Médica. 13th ed. Elsevier; 2016.
- Azzato F, Waisman HJ. Abdomen agudo. Buenos Aires, Argentina: Editorial Médica Panamericana; 2008.
- Cline DM, John O, Cydulka RK, Meckler GD, Thomas SH, Handel D. Tintinalli's Emergency Medicine Manual. 7th ed. New York, NY: McGraw-Hill Medical; 2012.
- Mouraux A, Plaghki L, Le Bars D. Fisiología del dolor: mecanismos centrales y controles. EMC - Anest-Reanim. 2018;44(4):1–22.
- Cadenas JAA, de la Torre Espí M. Diagnóstico y tratamiento del dolor abdominal agudo (abdomen agudo) en Urgencias [Internet]. Aeped.es. [cited 2021 Sep 4]. Available from: https://www.aeped.es/sites/default/files/documentos/16_abdomen_agudo.pdf
- Muñoz-Santanach D, Luaces Cubells C. Dolor abdominal agudo [Internet]. Pediatríaintegral.es. [cited 2021 Sep 4]. Available from: https://www.pediatríaintegral.es/wp-content/uploads/2019/xxiii01/02/n1-015-024_CarlesLuaces.pdf
- Nakayama DK. Examination of the acute abdomen in children. J Surg Educ. 2016;73(3):548–52.
- Krüger PC, Mentzel HJ. Radiologische Abklärung des akuten Abdomens im Kindesalter. Radiologe. 2019;59(2):146–53.
- Warner J, Desoky S, Tiwari HA, Morello F, Gilbertson D, Udayasankar U. Unenhanced MRI of the abdomen and pelvis in the comprehensive evaluation of acute atraumatic abdominal pain in children. AJR Am J Roentgenol. 2020;215(5):1218–28.
- Patterson JW, Kashyap S, Dominique E. Acute Abdomen. En: StatPearls. Treasure Island (FL): StatPearls Publishing; 2021.
- Ooms N, Matthyssens LEM, Draaisma JM, de Blaauw I, Wijnen MHWA. Laparoscopic treatment of intestinal malrotation in children. Eur J Pediatr Surg. 2016;26(4):376–81.
- Cacciatori FA, Ronchi AD, Sasso SE. Outcomes prediction score for acute abdomen: a proposal. Rev Col Bras Cir. 2020;46(6):e20192285.
- Marina C. Manual de pediatría. An Pediatr (Barc). 2020;59(5):524.